

SURGICAL MANAGEMENT OF BHAGANDARA BY IFTAK TECHNIQUE ALONG WITH ARAGWADHADI VARTI - A CASE STUDY

Piyush ranjan parhi¹ , Balendra Singh² , Satrupa Nirmal³ , Uttam kumar Nirmalkar ⁴ , Dheeraj Singh Baghel⁵ , Satish Kumar Chandravanshi⁶

¹ Corresponding Author - PG scholar, Dept. Of Shalyatantra , Shri Narayan Prasad Awasthi, Govt. Ayurveda College , Raipur , Chhattisgarh

² Professor and HOD , Dept. Of Shalyatantra , Shri Narayan Prasad Awasthi, Govt. Ayurveda College , Raipur , Chhattisgarh

³ Lecturer , Dept. Of Shalyatantra , Shri Narayan Prasad Awasthi, Govt. Ayurveda College , Raipur , Chhattisgarh

⁴ Reader , Dept. Of Shalyatantra , Shri Narayan Prasad Awasthi, Govt. Ayurveda College , Raipur , Chhattisgarh

⁵ Associate Professor , Dept. Of Shalyatantra , Shri Narayan Prasad Awasthi, Govt. Ayurveda College , Raipur , Chhattisgarh

Lecturer , Dept. Of Shalyatantra , Shri Narayan Prasad Awasthi, Govt. Ayurveda College , Raipur , Chhattisgarh

Corresponding Author : parhi.piyushranjan@gmail.com

ABSTRACT:

FISTULA is a condition in which two epithelial surfaces communicate abnormally. When a communication is established between anal canal and perineal region that condition is called as FISTULA-IN-ANO. The track is typically lined with unsightly granulation tissues. The primary cause of this condition is improperly treated cryptoglandular infection.¹ Over the advancement of time the Ksharasutra is still the best choice among treatment modalities available for Fistula-in-ano because of lesser complications like recurrence and incontinence.² Despite all these advantages, there are still certain drawbacks such as discomfort, prolonged periods of anxiety, increased hospital visits, extended treatment duration, and significant post-operative scarring, among others. IFTAK (Interception of Fistulous tract with application of Ksharasutra) is a novel advanced ksharasutra technique thus making it more convenient to patient as well as to exclude the drawbacks of conventional method. Further using Aragwadhadi varti along with the above said technique lead to better healing of the leftover portion of the track.³ Here in this case , IFTAK is done under Local anaesthesia. Kshara sutra was changed upto 4 weeks and aragwadhadi varti applied for 8 times . The fistula healed completely in 2 months . This study revealed an early complete remission of the fistulous tracts by IFTAK method and Aragwadhadi varti, When compared with the conventional kshara sutra method

. According to the length , the conventional method takes 15-20 weeks whereas in this study it took much less time . And during followup no recurrence was noted. Therefore, the IFTAK technique combined with Aragwadhadi varti was deemed highly effective due to its time-saving properties and reduced scar and fibrosis.

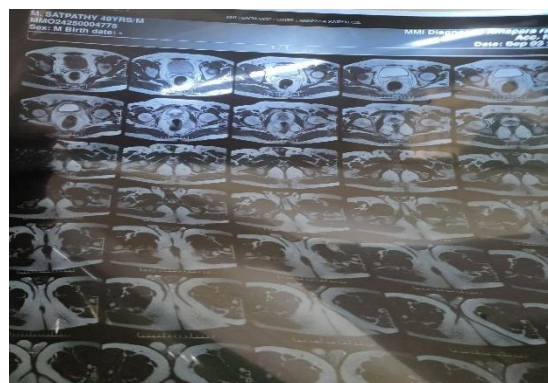


1.INTRODUCTION:

The untreated or improperly treated cryptoglandular infection is the most common cause of fistula in ano or Bhagandara .⁴ In this case study administration of IFTAK (Interception of Fistulous tract with application of ksharasutra) technique was done along with application of Aragwadhadi Varti in treating a complex intersphincteric fistula in Ano successfully Although the disease is not that much life threatening but produces severe inconvenience in routine life because of pus discharge and pain. By looking into the severity and chronicity of disease The Father of surgery Acharya Sushruta included Bhagandara in Asta Mahagada.⁵ There are numbers of treatment modalities available for the management of fistula in ano. Modern surgical management includes fistulotomy, fistulectomy, Seton placing, ligation of intersphincteric fistula tract (LIFT), fibrin glues, advancement flaps, and expanded adipose derived stem cells (ASCs).⁶ Acharya Sushruta has also described different therapeutic measures for the management

Bhagandara asin terms of various oral medications, local applications, surgical procedures and para-surgical intervention. Acharya Charaka has mentioned it under swayathu chikitsa adhyaya and kshara sutra ligation as its treatment.⁷ Presently Ksharasutra therapy is found most approaching and attractive treatment modality among para-surgical procedure for fistula-in-ano. Over the advancement of time the Ksharasutra is still the best choice among treatment modalities available for Fistula-in-ano because of lesser complications like recurrence and incontinence. But with all these benefits, still there are some consequences suffered by practitioners while practicing Ksharasutratheapy in relation to patients i.e. it causes discomfort, long anxiety period, number of hospital visits and longer duration of treatment, big post-operative scar etc. IFTAK (Interception of Fistulous tract with application of Ksharasutra) is an innovative ksharasutra technique rooted in this concept, thereby enhancing convenience for patients and avoiding the limitations of traditional methods.⁸ There are a number of choices in Ksharasutra like Apamarga based, papaya based, guggulu based or palasha based. But in this case we need to use Apamarga Ksharasutra because it has terrific result in cutting and healing the fistulous track.⁹ Thus, cases of fistula treated with this method can produce positive results. Additionally, utilizing Aragwadhadhi varti alongside the aforementioned technique might enhance the healing of the remaining track portion and reduce the likelihood of subsequent sinus recurrences. Because the indurated portion of the fistulous tract also needs to be healed properly along with the area near anal verge. Aragwadhadhi varti, as mentioned by Acharya Sushruta in the Bhagandara roga adhikara, may offer improved outcomes in reducing fibrosis of the fistulous tract and facilitate quicker healing compared to the standard treatment.

2. PRESENTING COMPLAINTS AND MEDICAL HISTORY:

A 44 year old male patient came to Shalya OPD of Shri Narayan Prasad Awasthi Govt. Ayurveda College, Raipur having Complaints of Intermittent pus discharge from perianal region along with Intermittent pain and itching since last 3 years. Patient was not having any Comorbidities. Patient got treated under various Doctors but did not get any satisfactory results. Endoanal Sonography and MRI fistulogram reports are attached below.



3. CLINICAL FINDINGS:

On examination perianal skin was normal. An external opening was present at 6 O'clock approximately 5 cm away from anal verge. On digital rectal examination, sphincter tone was normal tender dimpling or buttonhole-like opening noted at 6 O'clock at a distance of 2 cm inner to OS. On probing it was found that the probe goes upwards towards anal verge in a curvilinear manner. A single complete fistulous tract of about 6.5cm in length was found. A sinus of about 4.5 cm in length, perpendicular to the above tract was also found having a common external opening. Rest of the examinations were found to be normal and laboratory investigations were also found within normal limits.

4. TREATMENT:

After obtaining written consent and completing necessary pre operative procedures , the patient was placed in lithotomy position . After painting and draping , under Local anaesthesia probing was done to ascertain the finding . After confirming the diagnosis , a small vertical incision was made at 6 O'clock position at a distance of 1 cm near from anal verge and Interception of fistulous tract was done . Then a metallic probe was introduced through the window and taken out from the internal opening and kshara sutra ligation was done in the proximal tract .The kshara sutra was ligated loosely on initial days in order to facilitate proper drainage of pus . The residual distal tract was also ligated with ksharasutra in order to keep the tract patent (Fig.10). After achieving haemostasis dressing and packing done with Jatyadi taila and patient then shifted to male surgical ward . Patient was advised for regular hot sitz bath from post operative day 2. Patient was prescribed with Triphala guggulu 2 tab BD after food , Syp Abhayarista 15 ml BD with equal amount of water after food , Triphala churna 5 gm HS with luke warm water after food . On dressing from post operative day 2 , ksharasutra was removed from distal tract and antiseptic dressing done with Jatyadi Taila and Aragwadhadhi varti inserted in distal tract as well as in sinus(Fig 11) on every alternate days till the signs of Shuddha vrana appeared .

4.1. ARAGWADHADI VARTI:

In Sushruta Samhita, Aragwadhadhi varti is described in Treatment of Bhagandara.¹⁰ Aragwadhadhi varti has properties of Shodhana i.e Cleanses the tissue by scraping out unhealthy tissue and Ropana i.e Accelerates healing process by clearing debris tissue.¹¹ Powdered Haridra (*Curcuma longa*) and Tagara(*Valeriana wallichii*) taken in equal quantities and mixed in a well-balanced manner, followed by addition of Aragwadha(*Cassia fistula*) Majja, ghrita, and honey, all in equal quantities (Fig.4). The wicks were then prepared by hand, measuring 2 to 3 inches in length, and dried in the sun(Fig.5). Once the wicks dried and hardened, they were sterilised in UV chambers and then placed in air-tight containers. Aragwadhadhi varti was prepared in the Department of Rasa Shastra and Bhaishajya kalpana Of Shri N.P.A. Govt. Ayurveda College Raipur (C.G) according to classical reference. The ingredients of formulation Aragwadhadhi varti were collected from local fields and purchased from the market (Fig.2 & 3) and were authenticated by help of the Department of Dravya guna , Govt. Ayurveda college Raipur (C.G) . Moreover, further authentication was done from the Central research facility, KLE Academy of higher Education and Research , Karnataka (Fig. 1). Aragwadhadhi varti was sent to the Drug Testing Laboratory and Research Centre, Raipur (C.G) / NABL accredited lab for analysis of phytochemical and

physiochemical constituents . Drug Authentication Report, DTL report are attached hereby (Fig.6) .



Sl. No.	Common Name	Scientific Name	Family	Part extracted	CRF Code	Authenticated as			
						Sample Name	Scientific Name	Family	Part Authenticated
1.	Aragwada Majja	<i>Cassia fistula</i> Linn.	Cassiniaceae	Fruit Pulp	CRF/Amb/177/2024	Aragwada Majja	<i>Cassia fistula</i> Linn.	Cassiniaceae	Fruit Pulp
2.	Tagar	<i>Valeriana wallichii</i> DC.	Valerianaceae	Rhizome	CRF/Amb/178/2024	Tagar	<i>Valeriana wallichii</i> DC.	Valerianaceae	Rhizome
3.	Haridra	<i>Curcuma longa</i> Linn.	Zingiberaceae	Rhizome	CRF/Amb/179/2024	Haridra	<i>Curcuma longa</i> Linn.	Zingiberaceae	Rhizome
4.	Apamarga	<i>Achyranthes aspera</i> Linn.	Amaranthaceae	Whole Plant	CRF/Amb/180/2024	Apamarga	<i>Achyranthes aspera</i> Linn.	Amaranthaceae	Whole Plant

Fig.1



Fig.2




Fig.3



Fig.4



Fig.5

Fig.6

5.FOLLOWUP AND OUTCOMES:

Weekly follow up advised for Ksharsutra changing. Ksharsutra was changed three times after the first Ksharsutra was placed. The pus discharge was fluent in the first week from the artificially made window, gradually reduced and completely disappeared after two weeks(Fig 9). Pain was also moderate in the first week and later on gradually relieved. Pus discharge also diminished from the sinus tract after two weeks. The discharge from the external opening was also reduced gradually in 6-7 days and totally dried up in two weeks. (Fig 10) Then the ksharasutra was ligated tightly and Cut through was done (Fig 11) when discharge completely diminished from the artificial made window i.e. after three weeks of first Ksharsutra placed and complete healing was achieved in 15 days after cut through of proximal tract. Patient was advised for application of Jatyadi taila. The fistulous tract as well as the sinus healed simultaneously by 4th week with minimal scar and without any fibrosis (Fig 12). There was no complication seen during and after treatment and patient got free from all the symptoms. After 3 months of follow up, no recurrence is noted, the patient was cured completely .

PROBABLE MODE OF ACTION OF ARAGWADHADI VARTI:

Traditional treatments for wound healing include honey, Curcuma longa, Valerian wallichii, and Cassia fistula. Cassia fistula's anti-inflammatory, antibacterial, antifungal, and antioxidant qualities aid in wound closure, tissue regeneration, and enhanced healing.¹² Curcuma longa contains antibacterial, antioxidant, and anti-inflammatory qualities¹³, while Valerian wallichii possesses analgesic and anti-inflammatory qualities.¹⁴ As a natural antimicrobial, honey promotes quicker healing and reduced scarring by lowering inflammation, encouraging tissue development, and aiding autolytic debridement.¹⁵ Ghrita is a traditional Ayurvedic medication that decreases inflammation and speeds up wound contraction. Also it has been found that Aragwadhadi varti has a pH of 4.62, which is slightly acidic. Because it encourages quicker re-epithelialization, collagen deposition, and wound closure, a slightly acidic environment is optimal for wound healing.¹⁶ It also prevents the formation of dangerous microorganisms. Acidification promotes the migration of epithelial cells, increases oxygen release, and activates fibroblasts. By preventing the development of fibroblasts into myofibroblasts, which are in charge of collagen deposition and scarring, it may be able to lessen fibrosis.¹⁷ Collagen synthesis and fibrosis development can be inhibited by lowering pH levels in cell culture conditions.¹⁸

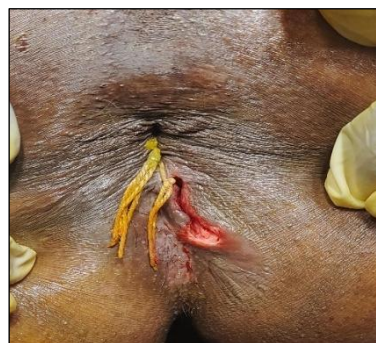

Fig.7

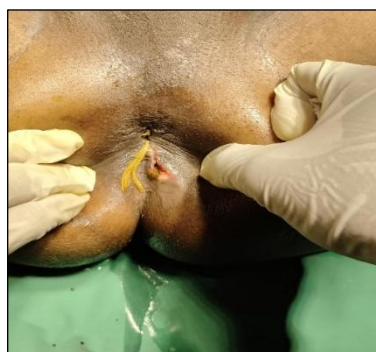

Fig.8

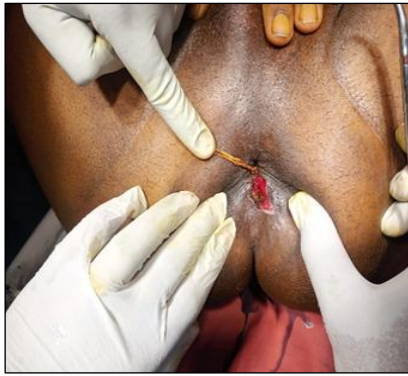

Fig.9

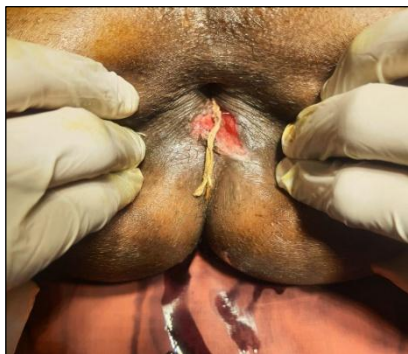

Fig.10

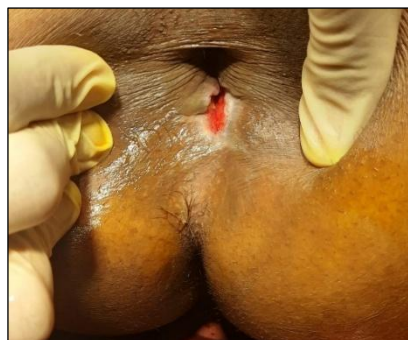

Fig.11

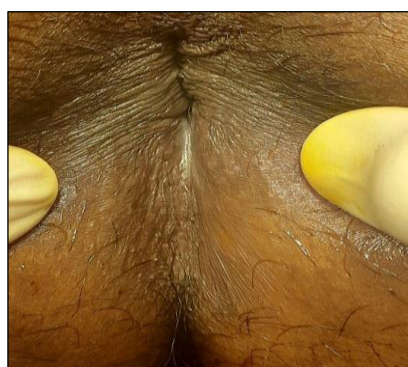


Fig.12

DISCUSSION :

Ksharasutra therapy is the most successful treatment modality for fistula in ano. Ksharasutra therapy has

high success rate¹⁹ and least recurrence rate (3.33%)²⁰. It is a highly simple day care option and an affordable treatment with a lower complication rate compared to traditional treatment methods that involve hospitalization, regional or general anesthesia, and frequent post-operative care. These surgical procedures carry a notable risk of recurrence (0.7–26.5%) and a considerable risk of reduced continence (5–40%)²¹. While Ksharasutra therapy is a preferred treatment for fistula in ano due to its various benefits, it does come with certain drawbacks, including discomfort, pain after the procedure, multiple hospital visits, extended treatment duration, significant post-operative scarring, and post-treatment fibrosis, resulting in low compliance and reduced acceptability among many patients. IFTAK (Interception of Fistulous tract and application of Ksharsutra) technique seems to overcome the limitations and consequences of conventional methods. Duration of therapy was less by shortening the length of the track and taking care of crypto glandular infection where there was no need to treat residual curved track. Pain was significantly reduced because of less exposure of tissues after interception which is from internal opening where as in conventional method whole track was exposed along the axis during the Ksharsutra change which increases the pain and burning sensation because of more tissue exposure. In this case study, the external opening was approximately 6.5 cm from the anal verge at the 6 o'clock position, and interception occurred at the 6 o'clock position about 1.0 cm from the anal verge, thus decreasing the length of the tract. Consequently, the IFTAK technique shortened the total healing time and significantly decreased pain while leaving minimal scarring.²² Aragwadhadhi varti purified the leftover tract and the sinus tract due to its Shodhana and Ropana properties. The patient was fully healed within two months, and no recurrence was observed during the three-month follow-up. Tablet Triphala Guggulu were used to counter inflammation, pain and to prevent infection. Triphala Guggulu tablets were utilized to alleviate inflammation, relieve pain, and guard against infection. Triphala guggulu has demonstrated antimicrobial properties.²³ Thus, it may be useful in prevention of infection and promote wound healing also. Triphala has antibacterial action against a variety of Gram-positive and Gram-negative bacteria and immunomodulatory effect.²⁴ And as per Ayurveda, Triphala exhibits Anulomana properties, which helps balance Apana Vata and promotes smooth bowel movements. The local use of Jatyadi Taila is said to notably enhance the levels of protein, hydroxyproline, and hexosamine in granulation tissue, facilitating quicker healing.²⁵ So, IFTAK is a sophisticated and efficient method in the area of fistula that features significant innovation and numerous advantages. Additionally,

Aragwadhadi varti functions like the cherry atop a cake when it comes to cleaning the fistulous tract, enhancing wound healing, and preventing fibrosis following complete recovery.

7. CONCLUSION:

Therefore, the research concluded that IFTAK, in conjunction with the use of Aragwadhadi Varti, is a secure, efficient, and progressive method that reduces post-operative duration while improving mild post-procedural pain and minimizing scar marks.

8. REFERENCES:

1. Kumar A, Bilyan A. IFTAK an innovative technique in fistula in ano-A casestudy. Ayur pub 2018; 2:771e5.
2. Deshpandey PJ, Sharma KR. Treatment of fistula in anorectal region, review and follow up of 200 cases. Am J Proctol 1973; 24:49e60
3. Sushruta, Sushruta Samhita, Part-I, Ayurveda Tatwa Sandeepika Hindi Commentary, Edited by Kaviraj Ambika Dutta Shastri, chikitsa stana-Bhagandarachikitsa Adhyaya 8/30, Chaukhamba Sanskrit Sansthan, Varanasi, Edition-13, 2002,Page no. 60.
4. Kumar A, Bilyan A. IFTAK an innovative technique in fistula in ano-A casestudy. Ayur pub 2018; 2:771e5.
5. Sushruta Samhita, Part-I, Ayurveda Tatwa Sandeepika Hindi Commentary, Edited by Kaviraj Ambika Dutta Shastri, Sutrastana- Avarniya Adhyaya 33/4, Chaukhamba Sanskrit Sansthan, Varanasi, Edition-13, 2002, Page no. 126.
6. Limura E, Giordano P. Modern management of anal fistula. World J Gastroenterol 2015;21(1):12e20. <https://doi.org/10.3748/wjg.v21.i1.12>.
7. Charaka Samhita, part 2 , uttarardha ,Vidyotini Teeka Hindi commentary, edited by Kashinath pandey shastri, chikitsa sthana – swayathu chikitsa 12/97, Chaukhamba Sanskrit sansthan , Varanasi, Edition 13, 2021, Page no – 342.
8. Diwan S, Kumar P, Gupta SJ. IFTAK-An advanced technique of Kshara Sutrathrapy in management of complex Fistula-In-Ano-A Case Study. J Ayurveda Integrated Med Sci 2019;3(6):181e4 (ISSN 2456-3110).
9. Kumar A. Current trends in the usage of ksharakarma (alkaline therapy) and ksharasutra (alkaline seton) for managing bhagandhara (fistula -in ano).J. res. tradit. med 2018;4(2):70e7.
10. Sushruta, Sushruta Samhita, Part-I, Ayurveda Tatwa Sandeepika Hindi Commentary, Edited by Kaviraj Ambika Dutta Shastri, chikitsa stana-Bhagandarachikitsa Adhyaya 8/30, Chaukhamba Sanskrit Sansthan, Varanasi, Edition-13, 2002,Page no. 60.
11. Senthil Kumar M, Sripriya R, Vijaya Raghavan H, Sehgal PK. Wound healing potential of Cassia fistula on infected albino rat model. J Surg Res. 2006 Apr;131(2):283-9. doi: 10.1016/j.jss.2005.08.025. Epub 2005 Oct 20. PMID: 16242721.
12. Tejada S, Manayi A, Daglia M, Nabavi SF, Sureda A, Hajheydari Z, Gortzi O, Pazoki-Toroudi H, Nabavi SM. Wound Healing Effects of Curcumin: A Short Review. Curr Pharm Biotechnol. 2016;17(11):1002-7. doi: 10.2174/1389201017666160721123109. PMID: 27640646.
13. Li J, Li X, Wang C, Zhang M, Ye M, Wang Q. The potential of Valeriana as a traditional Chinese medicine: traditional clinical applications, bioactivities, and phytochemistry. Front Pharmacol. 2022 Sep 21;13:973138. doi: 10.3389/fphar.2022.973138. PMID: 36210806; PMCID: PMC9534556.
14. Ahmad Oryan, Esmat Alemzadeh, Ali Moshiri, Biological properties and therapeutic activities of honey in wound healing: A narrative review and meta-analysis, Journal of Tissue Viability, Volume 25, Issue 2, 2016, Pages 98-118, ISSN 0965-206X, <https://doi.org/10.1016/j.jtv.2015.12.002>. (<https://www.sciencedirect.com/science/article/pii/S0965206X15000972>)
15. Sim P, Strudwick XL, Song Y, Cowin AJ, Garg S. Influence of Acidic pH on Wound Healing In Vivo: A Novel Perspective for Wound Treatment. Int J Mol Sci. 2022 Nov 7;23(21):13655. doi: 10.3390/ijms232113655. PMID: 36362441; PMCID: PMC9658872.
16. Sim P, Song Y, Yang GN, Cowin AJ, Garg S. In Vitro Wound Healing Properties of Novel Acidic Treatment Regimen in Enhancing Metabolic Activity and Migration of Skin Cells. Int J Mol Sci. 2022 Jun 28;23(13):7188. doi: 10.3390/ijms23137188. PMID: 35806191; PMCID: PMC9266998.
17. Pankaj S, Manoranjan S. Efficacy of Ksharsutra (medicated seton), therapy in the management of fistula-in-ano. World J Colorectal Surg 2010;2(2) (Art. 6:01e10).
18. Panigrahi HK, Rani R, Padhi MM, Lavekar GS. Clinical evaluation of Ksharasutra therapy in the management of Bhagandara (fistula-in-ano) da prospective study. Anc

- Sci Life 2009;28(3):29e35 [PMC free article] [PubMed].
19. Dutta G, Bain J, Ray AK, Dey S, Das N, Das B. Comparing Ksharasutra (Ayurvedic Seton) and open fistulotomy in the management of fistula-in-ano. *J NaSci Biol Med* 2015;6(2):406e10. <https://doi.org/10.4103/0976-9668.160022>. PMID: 26283840; PMCID: PMC4518420.
 20. Sahu M. published by. In: A manual on fistula in ano and kshara sutra therapy. 1st ed. NRC, Deptt. Of ShalyaTantra, IMS, BHU; 2015.
 21. Mhaikar Bhushan D, Bharat Chouragad Bari. Management of non-healing infected wound by external application of and Hinsradya Taila TriphalaGuggulu. *Joinsysmed* 2017;5(2):130e4.
 22. Tarasiuk A, Mosinska P, Fichna J. Triphala: current applications and new perspectives on the treatment of functional gastrointestinal disorders. *Chin Med* 2018;13:39. <https://doi.org/10.1186/s13020-018-0197-6>. PMID: 30034512; PMCID: PMC6052535.
 23. Shailajan S1, Menon S, Pednekar S, Singh A. Wound healing efficacy of Jatyadi Taila: in vivo evaluation in rat using excision wound model. *J Ethnopharmacol* 2011;138(1):99e104. <https://doi.org/10.1016/j.jep.2011.08.050>. Epub 2011 Aug 30.